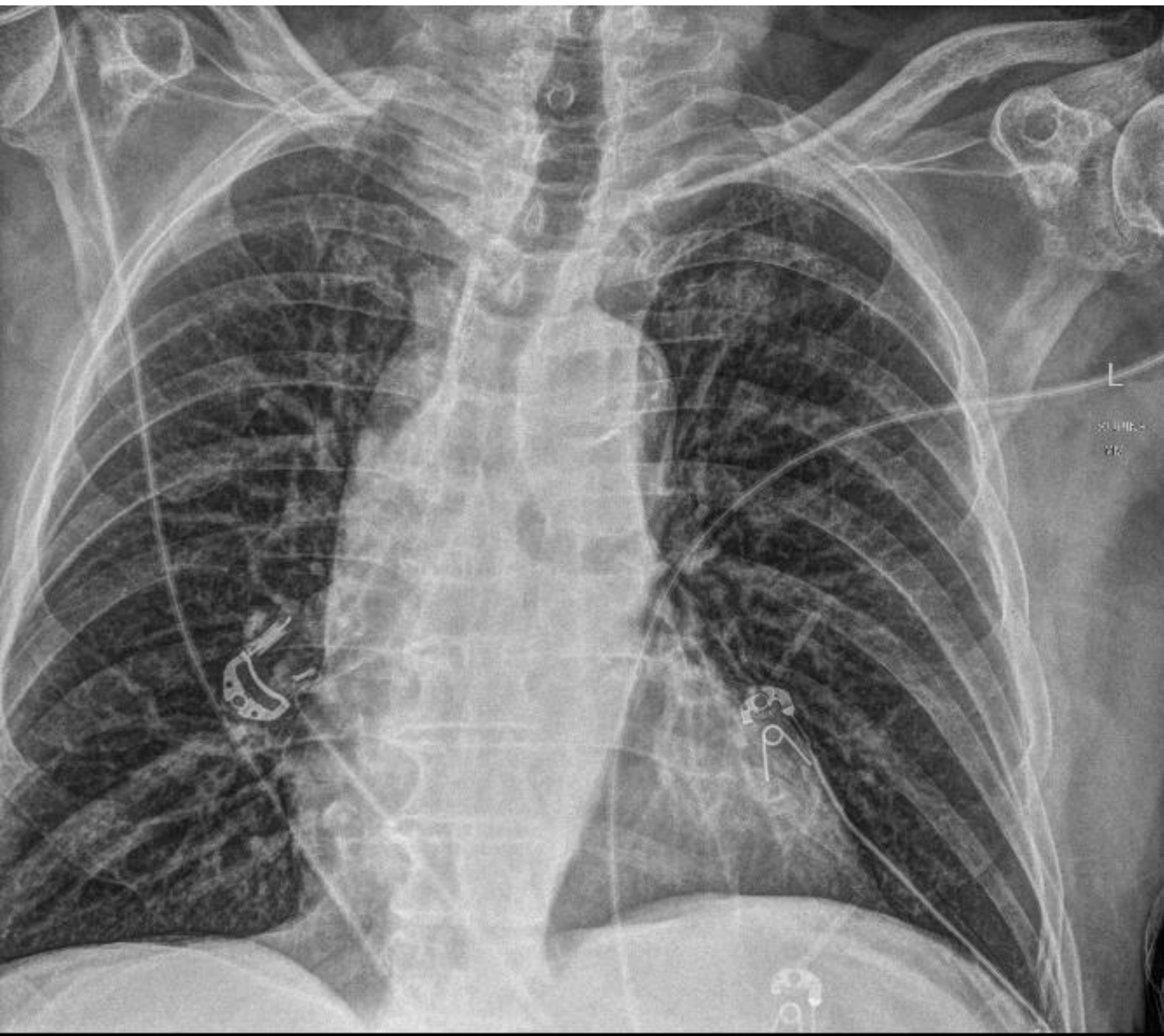
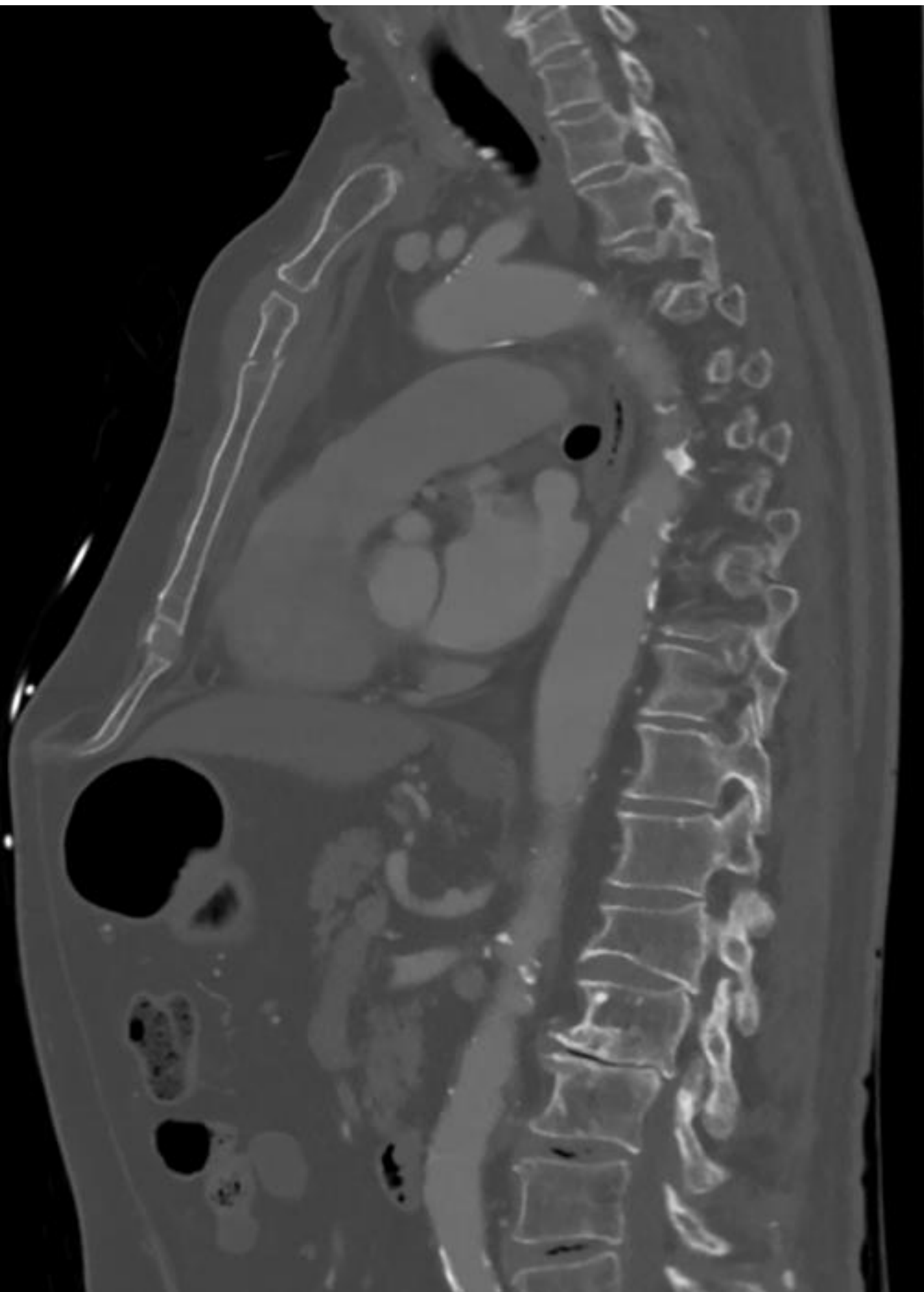


CXR – supine, nil major injury noted



CT – proximal sternal fracture and small associated retrosternal haematoma



# HsTnl (Troponin I)

Cardiac Markers

Specimen: Blood

cTroponin I (Atellica)

8 ng/L (< 54)

# ECG

