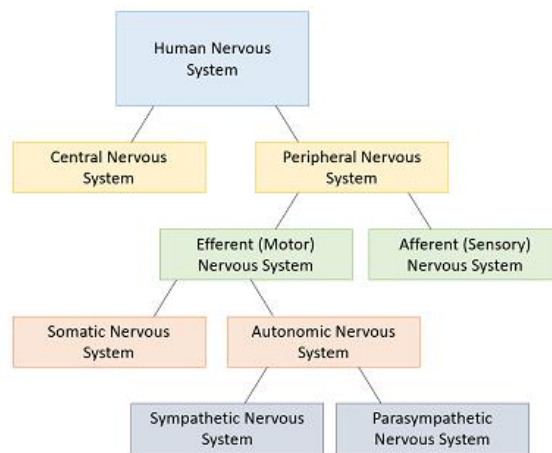


Neuroanatomy – An overview

Nervous System

The nervous system is divided into the central nervous system, which consists of the brain and spinal cord (upper motor neurons) and the peripheral nervous system (nerves entering and exiting the spinal cord). The peripheral nervous system is further divided into the somatic and autonomic nervous system. The somatic system relays information about the body’s conscious activity, such as actions of skeletal muscles. The autonomic system regulates involuntary or unconscious activity such as heart rate, blood pressure, breathing, digestion, etc.



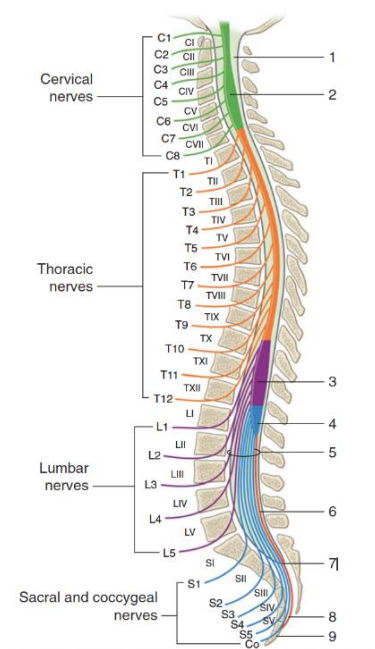
Spinal Cord

The vertebral column consists of 33 vertebrae that are divided into five sections

- 7 cervical
- 12 thoracic
- 5 lumbar
- 5 sacral and 6 coccygeal vertebrae, with the sacral fusing to form the sacrum and the coccygeal fusing to form the coccyx.

The spinal cord nerve roots do not relate to the cervical vertebral bodies, as they exit and enter the spinal cord above and below the vertebra. Meaning there are 7 cervical vertebrae and 8 cervical nerve roots.

The spinal cord extends from the foramen magnum to the T12/L1 vertebrae/disc. The spinal nerves below this level is known as the Cauda Equina. The cord tapers into the conus medullaris and terminates at L1/2 in adults.



Tracts

Ascending Tracts (Sensory)

Spinothalamic Tract

- Carries information about pain, temperature, crude touch and pressure

Spinocerebellar Tract

- Carries unconscious proprioception to the cerebellum, which is responsible for muscle coordination

Fasciculus Gracilis and Fasciculus Cuneatus

- Carries information regarding discriminative touch (Gracilis) and conscious proprioception (Cuneatus)
- Discriminative touch allows you to localise the location of touch
- Fibres cross at the level of the brainstem

Descending Tract (Motor)

Corticospinal Tract

- This tract originates in the cerebral cortex where voluntary motor control is localised.
- These upper motor neurons synapse with lower motor neurons leading to skeletal muscles

Other Resources

Video on ascending and descending tracts

[Spinal Pathways/Tracts - Part 2 - Ascending and Descending Tracts Overview - Anatomy Tutorial - YouTube](#)

Mechanism of Injury

The forces that result in spinal fractures are rarely pure in direction and don't necessarily correlate to the severity of spinal cord injury. The spinal cord is rarely severed in traumatic spinal cord injuries. Knowledge of the mechanisms of the injury provides an aid to the diagnosis of the SCI.

Traumatic

Common mechanisms of injury:

- Falls
- Diving
- Motor vehicle accidents
- Non-motor vehicle accidents (e.g. all-terrain vehicles, motorbikes)
- Animal related (e.g. horseback riding)
- Violence
- Sports

Atraumatic

Common mechanisms of injury:

- Vascular (i.e. haemorrhage, arteriovenous malformation, embolism)
- Tumour
- Inflammatory or infection (i.e. epidural abscess)

- Degenerative (i.e. osteoporosis)

Types of Deficits

Upper Motor Neuron (UMN)

- Injuries to the spinal cord, with paralysis, increased tone, hyperreflexia and spasticity
- Lesions above L1 vertebral level

Lower Motor Neuron (LMN)

- Injuries to cauda equina with paralysis, reduced tone, reduced reflexes and wasting
- Lesions below the L1 vertebral level
- Injuries to conus (T11-L1) may also be LMN

Mixed

- Injuries to conus and cauda equina e.g. UMN bladder and bowel + LMN paralysis in legs
- Injuries involving the spinal cord itself plus the exiting nerve roots at that level may cause LMN lesion in the segments supplied by the nerve root and UMN paralysis below the level

Spinal Cord Syndromes

Anterior Cord Syndrome:

- Most common
- Damage to anterolateral grey and white (anterolateral tracts) matter
- Loss of pain and temperature and motor function
- Sparing of posterior columns
- Usually, flexion injuries with stretch injury to vertebral vessels and ischaemia

Central Cord Syndrome:

- Most often in older people with pre-existing degenerative disease of vertebral column
- Usually, hyperextension injuries with minimal bony injury
- Central part of the cord affected most and upper limb more affected than other limbs

Brown – Sequard Syndrome:

- Hemi-section of the cord
- Common with shooting or stabbings
- Loss of motor function and proprioception on the side of the lesion and pain and temperature on the contralateral side

Posterior Cord Syndrome:

- Is rare in traumatic injuries
- Loss of proprioception, vibration and pressure sensation

Sacral Sparing:

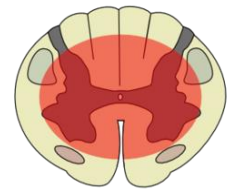- Preservation of pain and temperature in the sacral dermatomes
- Sacral fibres are the most lateral in the spinal cord and therefore the last to lose their blood supply

Cauda Equina Lesions:

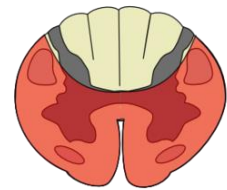
- These are often incomplete because of the wide neural canal and mobility of the nerve roots
- LMN lesions with potential for neurological regrowth and recovery if the nerve roots are not divided

Incomplete lesions of the spinal cord

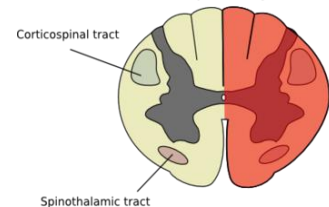
Central Cord Syndrome



Anterior Cord Syndrome



Brown-Séquard Syndrome



Autonomic Dysfunction

Cardiovascular impairment post SCI is generally elevated with higher level injuries. This is due to unbalanced autonomic control; the sympathetic outflow is reduced, and parasympathetic activity is unopposed due to the intact vagal nerve. Clinically this can present as bradycardia, low resting blood pressure and arrhythmias.

Possible Complications

Autonomic Dysreflexia (AD)

AD is a medical emergency that is caused by a noxious stimulus arising below the level of injury resulting in a sympathetic response. This typically affects individuals with injury at the T6 level and above. Symptoms can vary from being asymptomatic, mild or severe. AD typically presents with elevated blood pressure, reduced heart rate, blurry vision, headache and a blotchy rash on the chest and face. If left untreated it can result in a stroke, seizures or death.

Management:

- Check for possible causes (i.e. empty or unkink catheter, loosen tight clothing)
- Sit upright
- Some individuals will carry medication with them (e.g. nitroglycerine or glyceryl trinitrate)
- Contact emergency services if unable to resolve quickly

Other Resources

QSCIS Autonomic Dysreflexia Fact Sheet

- [Management of Autonomic Dysreflexia \(health.qld.gov.au\)](https://www.health.qld.gov.au)

Syringomyelia

The formation of a cyst or “syrinx” filled with cerebrospinal fluid within the spinal cord. This can occur within the first few months after injury or years later. A syrinx presents with altered motor and sensory function at the level of the collection, which can have significant impacts of functional ability and independence.

References

Reznik, J., Simmons, J. (2020). Rehabilitation in spinal cord injuries (1st ed.). Elsevier Health Sciences.