



Queensland
Trauma Education

EXTREMITY TRAUMA

Ankle fracture

Case discussion

Facilitator resource kit

CSDS



Clinical Skills Development Service



Queensland Trauma Education

The resources developed for Queensland Trauma Education are designed for use in any Queensland Health facility that cares for patients who have been injured as a result of trauma. Each resource can be modified by the facilitator and scaled to the learners needs as well as the environment in which the education is being delivered, from tertiary to rural and remote facilities.

Developed by

Dr Frances Williamson, Staff Specialist Emergency Physician – Metro North Health

Reviewed by

Kimberly Ballinger, Simulation Educator – Clinical Skills Development Service

Education Working Group, Statewide Trauma Clinical Network – Clinical Excellence Queensland

Queensland Trauma Education

Extremity Trauma – Ankle fracture: Case discussion – Training resource kit Version 1.0

Published by the State of Queensland (Clinical Skills Development Service), 2022



This document is licensed under a Creative Commons Attribution 3.0 Australia licence. To view a copy of this licence, visit <https://creativecommons.org/licenses/by/3.0/au>.

© State of Queensland (Metro North Hospital and Health Service through the Clinical Skills Development Service) 2022

You are free to copy, communicate, and adapt the work, as long as you attribute the Metro North Hospital and Health Service through the Clinical Skills Development Service. For more information, please contact Clinical Skills Development Service, Royal Brisbane and Women's Hospital, Herston, Queensland +61 3646 6500, CSDS-Admin@csds.qld.edu.au.

An electronic version of this document is available via csds.qld.edu.au/qte

Disclaimer: The content presented in this publication is distributed by the Queensland Government as an information source only. The State of Queensland makes no statements, representations or warranties about the accuracy, completeness or reliability of any information contained in this publication. The State of Queensland disclaims all responsibility and all liability (including without limitation for liability in negligence) for all expenses, losses, damages and costs you might incur as a result of the information being inaccurate or incomplete in any way, and for any reason reliance was placed on such information.

About this training resource kit

This resource kit provides healthcare workers with the knowledge and skills to effectively interpret ankle x-rays for correct alignment following injury.

National Safety and Quality Health Service (NSQHS) Standards



Target audience

- Emergency department medical and nursing clinicians
- Physiotherapists

Duration

30 minutes

Group size

Suited to small group participation

Learning objectives

By the end of this session the participant will be able to:

- Discuss the classification of ankle fractures
- Understand the concept of procedural sedation
- Recognise adequate reduction of ankle fractures and immobilisation

Facilitation guide

1. Facilitator to use resource to deliver session on ankle fractures
2. Learner needs will dictate depth of discussion regarding anaesthetic process

Supporting resources

- Case courtesy of Assoc Prof Frank Gaillard
- Lemon Airway assessment method
- Question and answer guide

Overview of ankle fractures

Ankle fractures are common and often occur following a twisting trauma mechanism. Clinical rules, including Ottawa Ankle Rule, may be used to delineate which patients require Xray imaging. Injury profile, including fracture displacement, ankle stability and overlying wounds in conjunction with patient factors will determine patient treatment plans. The emergent management involves ensuring wound care is performed if required, assessment of neurovascular injury is performed and joint alignment is achieved in the splinting device chosen.

Further reading

Reduction of Common Fractures and Dislocations	
Source	International Emergency Medicine Education Project
Link	https://iem-student.org/reduction-of-common-fractures-and-dislocations/

Ankle fractures	
Source	Orthobullets
Link	https://www.orthobullets.com/trauma/1047/ankle-fractures

Guideline on sedation and/or analgesia for diagnostic and procedures	
Source	Australian and New Zealand College of Anaesthetists (ANZCA)
Link	https://bit.ly/3fTv3uZ

Additional resources

Informed Consent: patient information. Sedation with your procedure	
Source	Queensland Health
Link	https://bit.ly/3qP6s0F

Fracture Ankle. Procedural consent form and patient information form.	
Source	Queensland Health
Link	https://bit.ly/3rubqPs

Emergency Medicine Procedural Sedation Consent form	
--	--

Source	RBWH
--------	-------------

Link	https://bit.ly/3lcG5Hu
------	---

Procedural Sedation Record	
-----------------------------------	--

Source	Queensland Health
--------	-------------------

Link	https://bit.ly/3qEH8tW
------	---

Procedural Sedation Record	
-----------------------------------	--

Source	TPCH
--------	------

Link	https://bit.ly/3nCUUvm
------	---

Fracture Emergency Department, Fact Sheets	
---	--

Source	Clinical Excellence Division
--------	-------------------------------------

Link	https://bit.ly/3fl2SPa
------	---

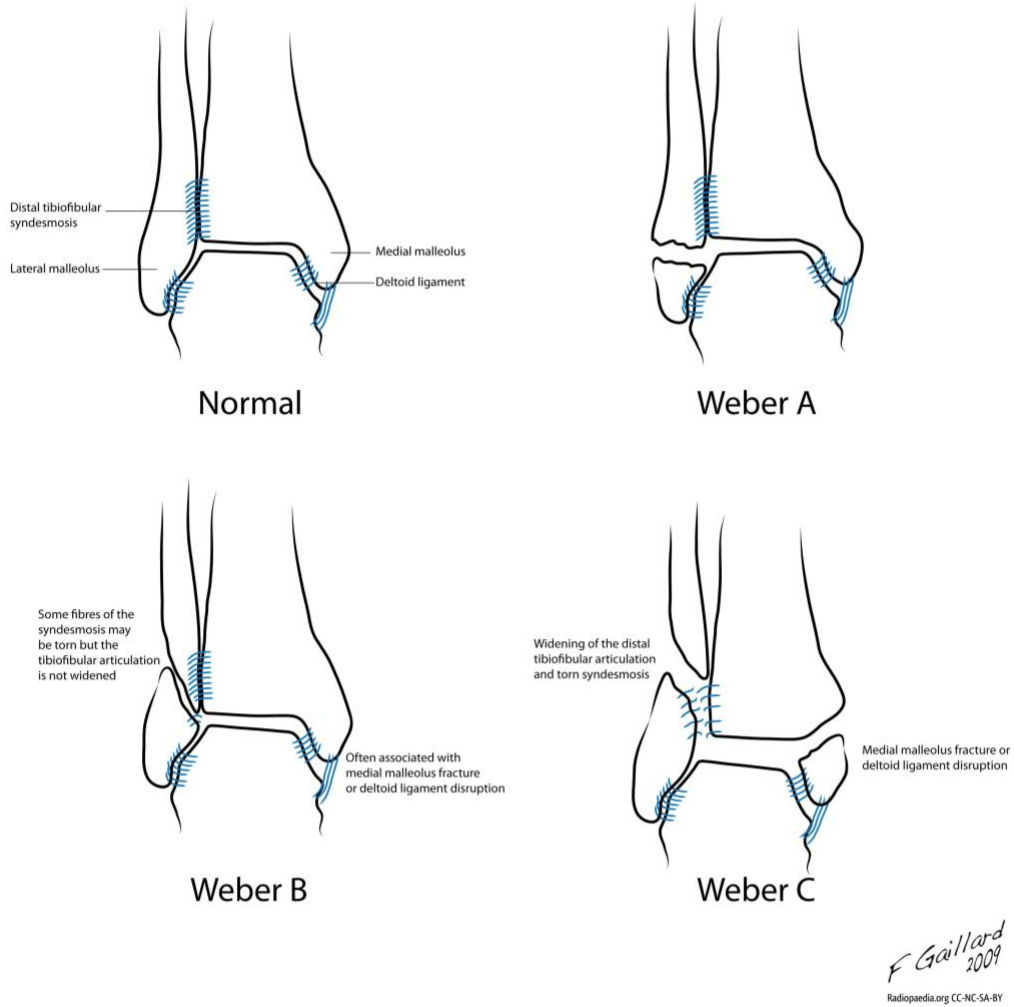
Plaster Cast care	
--------------------------	--

Source	Metro North Health
--------	--------------------

Link	https://bit.ly/3fl2SPa
------	---

Supporting resources

Case courtesy of Assoc Prof Frank Gaillard, Radiopaedia.org



Lemon Airway assessment method

Source: [Conference Notes 1-24-2018 — APMC EM \(christem.com\)](#)

L	Look externally (Facial trauma, large incisors, beard or moustache, large tongue)
E	Evaluate the 3-3-2 rule <ul style="list-style-type: none">- Incisor distance: 3 FB- Hyoid-mental distance: 3 FB- Thyroid-to-mouth distance: 2 FB
M	Mallampati Score ≥ 3
O	Obstruction : Presence of any condition like epiglottitis, Peritonsillar abscess, trauma
N	Neck Mobility (Limited neck mobility)

Case discussion

Case study

A 48yo male presents to the Emergency Department following a fall off a motorised scooter at low speed. He has an isolated lower L leg injury. His clinical exam reveals swelling and tenderness over the anterior and lateral aspect of the ankle joint, with intact movement of his toes and normal sensation to his foot and an ankle Xray is taken.

PMHx: alcohol dependence- drinks 10-15 standard drinks/day.

No regular medications, nil allergies.

Previous General Anaesthetic tolerated with no complications.

Question and answer guide

1. Discuss the features and type of ankle fracture shown on the Xray (Xray 1: AP and Lateral).

Facilitator to show Xray 1: AP and Lateral for interpretation.

Oblique fracture of the distal fibula at the level of the syndesmosis (Weber B).

There is associated syndesmotic widening and lateral talar shift/tilt of the talus. Tiny avulsion fracture of the tip of the medial malleolus, displaced distally.

Marked bilateral malleolar soft tissue swelling. No posterior malleolar fracture.

2. What is the Weber classification of ankle fractures?

See infographic Weber fracture classification.

Weber fracture classification system is used to describe lateral malleolar fractures, with the level of the fracture related to the ankle joint and any syndesmosis injury. The classification system can aid management decisions by determining who requires operative management.

Weber A: below the level of the syndesmosis (infrasyndesmotic), usually stable if the medial malleolus intact.

Weber B: injury at the level of the syndesmosis (transsyndesmotic), may extend proximally. Usually spiral fracture of the fibula. Can have widening of the distal tibiofibular joint, indicating syndesmotic injury. There is variable stability and may require ORIF (open reduction internal fixation).

Weber C: above the level of the syndesmosis (suprasyndesmotic). Widening of the distal tibiofibular articulation. Need to assess the proximal fibula for Maisonneuve fracture. Unstable injury usually requiring ORIF.

3. What management does this patient require?

- This fracture/dislocation pattern is unstable as described as a Weber B with significant talar shift laterally.
- The ankle needs to be reduced to anatomic position and referred to orthopaedics for ORIF.
- ORIF is indicated as there is >3mm of talar shift present.

4. How is a closed reduction achieved?

The patient will require anaesthetic to undertake the reduction.

Options to achieve this include:

1. Procedural sedation
2. Regional anaesthesia
3. General anaesthetic

Decision will be based on availability and skill mix of the treating team.

5. What are the general indications for emergent reduction of fractures in the Emergency Department?

1. Vascular compromise
2. Neurological impairment
3. Skin at risk (tenting)
4. Significant deformity
5. Pain

6. A procedural sedation in the Emergency Department will be performed to allow emergent reduction of this injury. What are the elements for the safe delivery of sedation in this setting?

Consideration for the environment, team, skill mix and patient factors to determine suitability for procedural sedation outside the theatre setting.

Environment: procedural sedation techniques deliver anaesthetic and analgesic agents to allow the patient to have a deeper sedation but require appropriate safe environment to achieve this. It should only be performed in a resuscitation environment with appropriate airway, breathing and circulation equipment immediately available for use if required. The ability to recognise and manage complications including airway compromise and anaphylaxis.

Team and skill mix: to deliver safe sedation in the ED the team need to have appropriate experience and undergo credentialling in procedural sedation procedures. This will vary between institutions. Team members required include a dedicated airway doctor and assistant, proceduralist and assistant and scribe.

Patient factors: prior to embarking on a procedural sedation the patient is assessed for potential difficult airway and high-risk features from sedation delivery. These can include the use of LEMON airway assessment, ASA assessment, fasting status and previous medication allergies/side effects. Regular use of alcohol and drugs should be considered when medication choice and dosing is determined.

- 7. A post-reduction repeat Xray is taken. Describe the position of the fracture and discuss the next steps (Xray 2: AP and Lateral).**

Facilitator to show Xray 2: AP and Lateral for interpretation.

There is improved alignment compared to the initial imaging, however there is persisting widening of the medial aspect of the ankle joint with lateral subluxation of the talus in relation to the distal tibia. There is improved alignment of the comminuted oblique fracture through the distal fibula but persisting dorsal and proximal subluxation of the distal fracture fragment.

The Xray reveals incomplete reduction. There is a risk of complications if left in this position and needs to be reduced to anatomical alignment. Anatomic reduction is considered the most important factor for a satisfactory outcome.

- 8. A decision to perform a second procedural sedation occurs and repeat Xrays are taken (Xray 3: AP and Lateral). Describe the position of the ankle fracture/dislocation now.**

Facilitator to show Xray 3: AP and Lateral for interpretation.

Improvement in alignment of the ankle fracture with near normal tibiotalar position.

- 9. The patient has recovered from their sedation. What clinical assessment should be made of the limb?**

A full neurovascular review to ensure no complications to nerve or vessel structures has occurred during the reduction process.

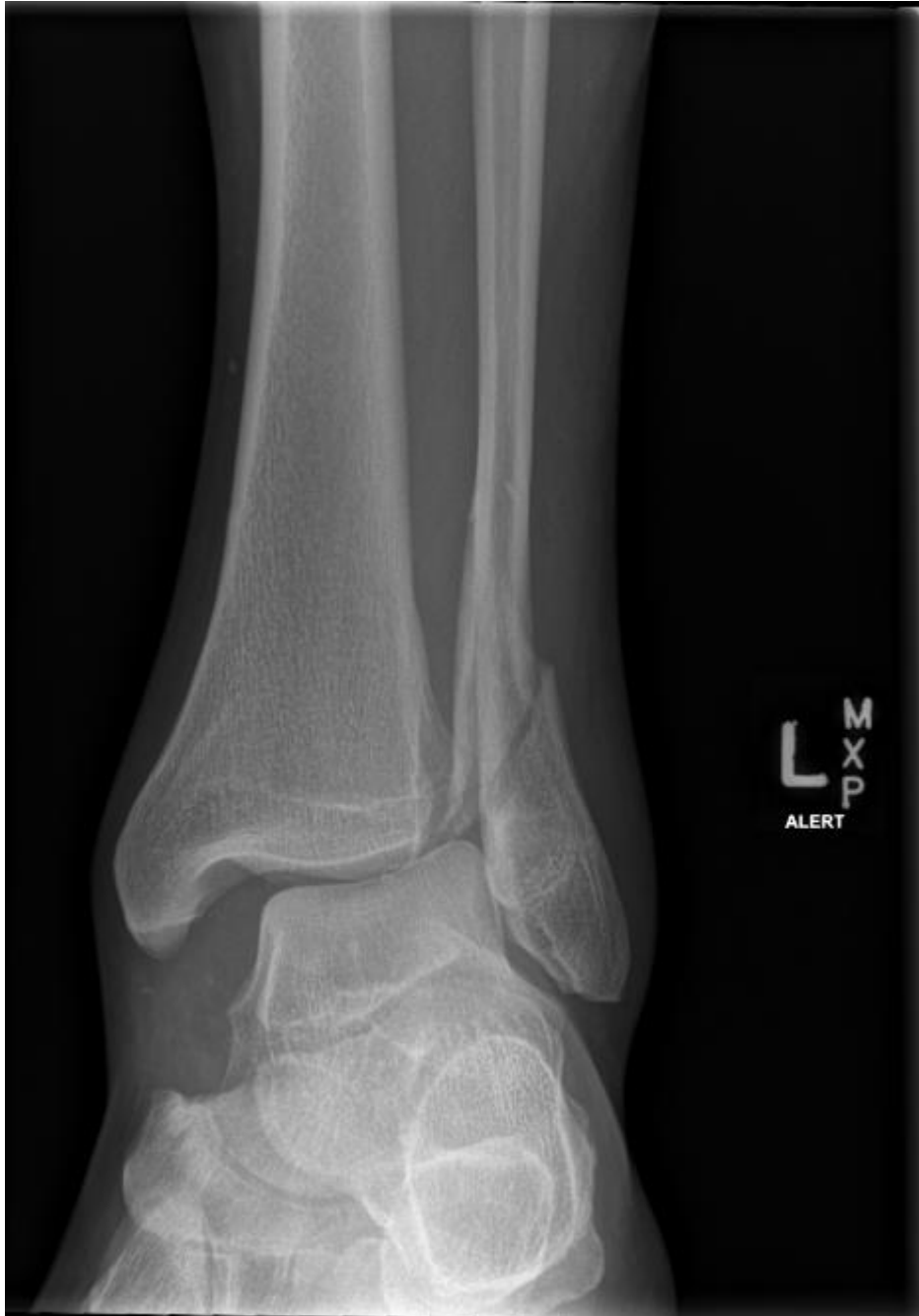- 10. The patient is reviewed by the orthopaedic team who agree the alignment is now appropriate and the patient will be booked for outpatient care. What information is given to the patient prior to discharge.**

1. Follow up plan- return for operative management or outpatient department (OPD) appointment (as per orthopaedic plan)
2. Analgesia plan - regular simple analgesia, step up analgesia instructions and use
3. Aperient management
4. Deep vein thrombosis prophylaxis consideration in high risk patient
5. Plaster care information
6. Return criteria for emergent review

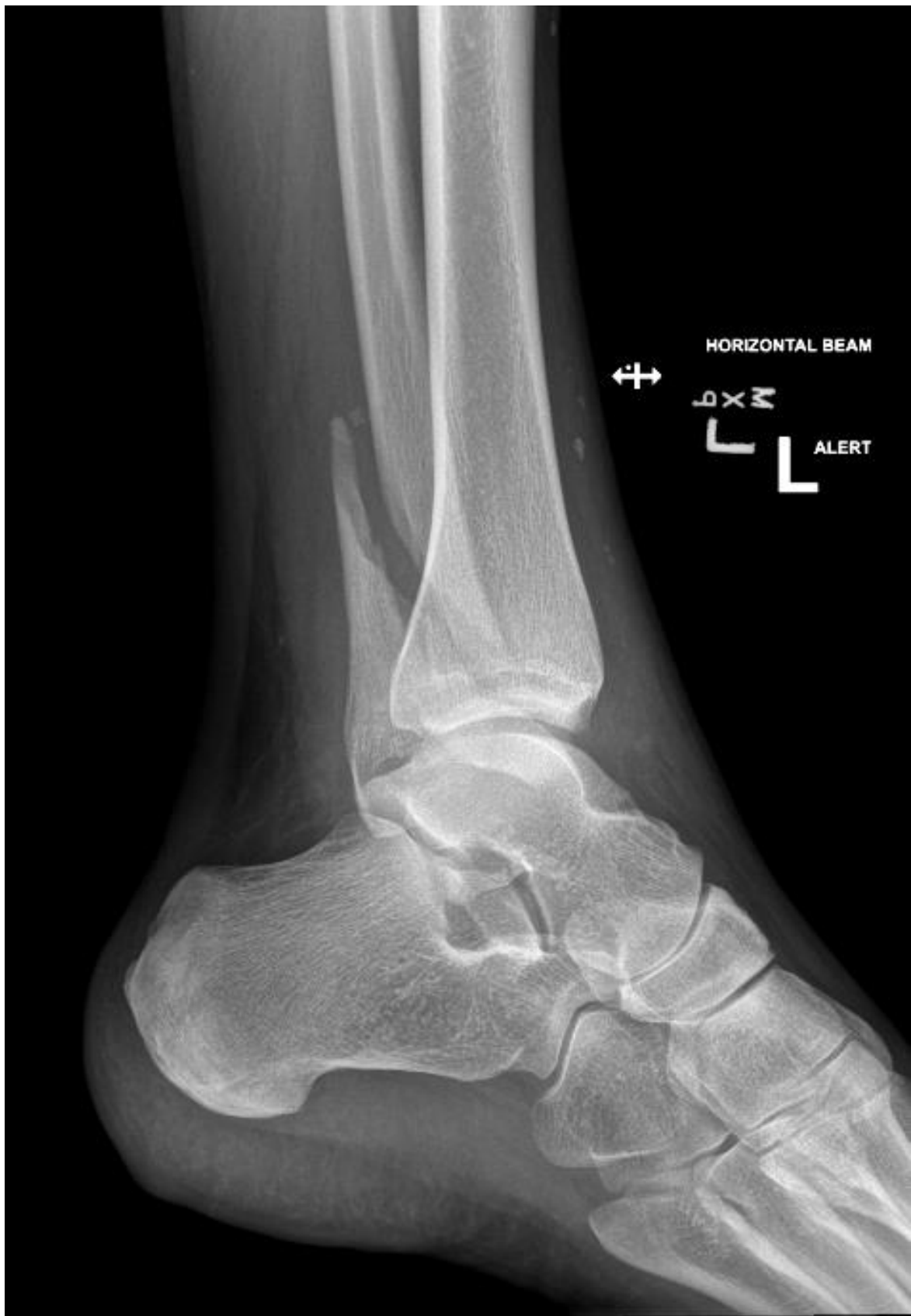Supporting documents

The following supporting documents are provided for this case discussion:

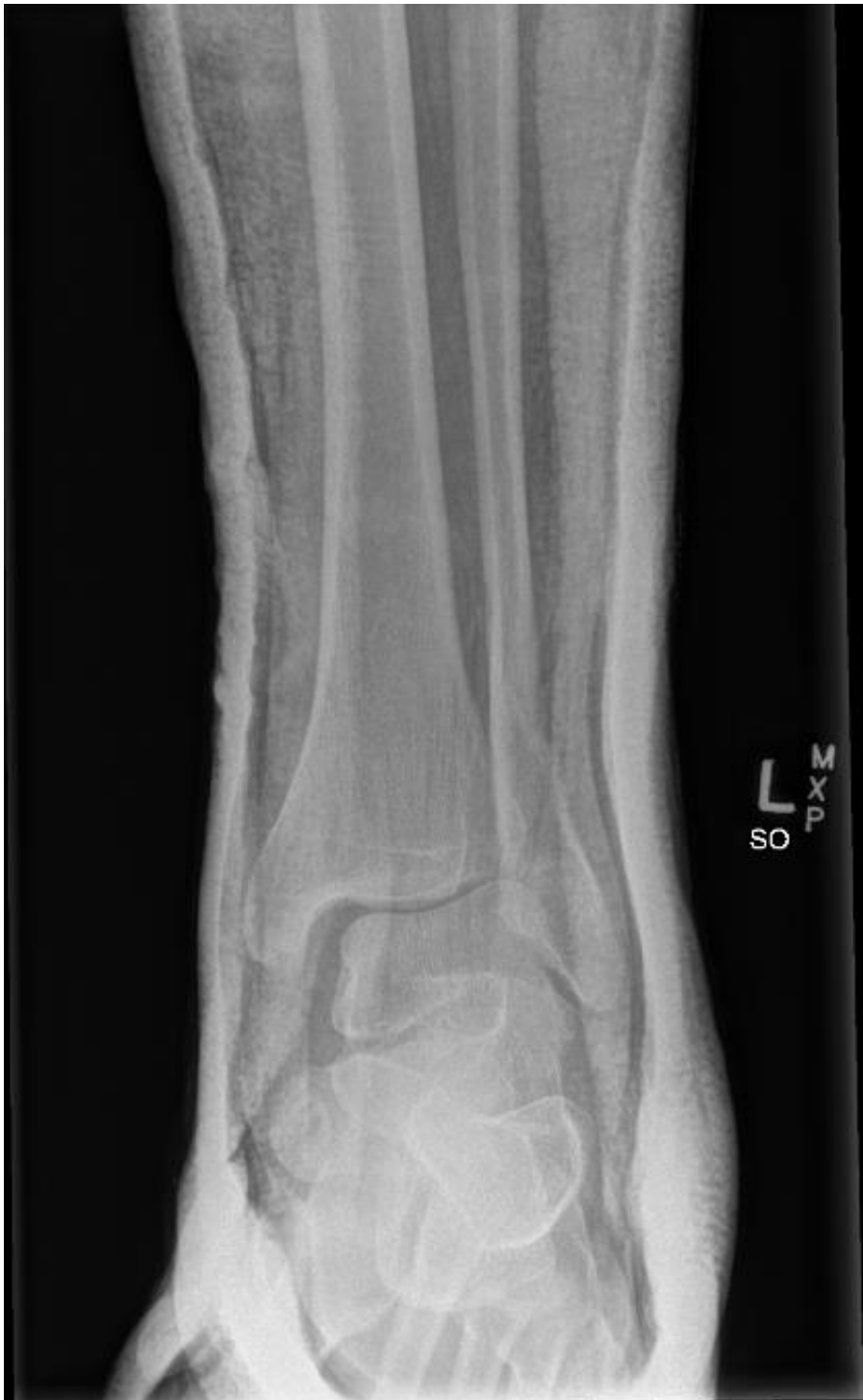1. L Ankle Xray 1: AP



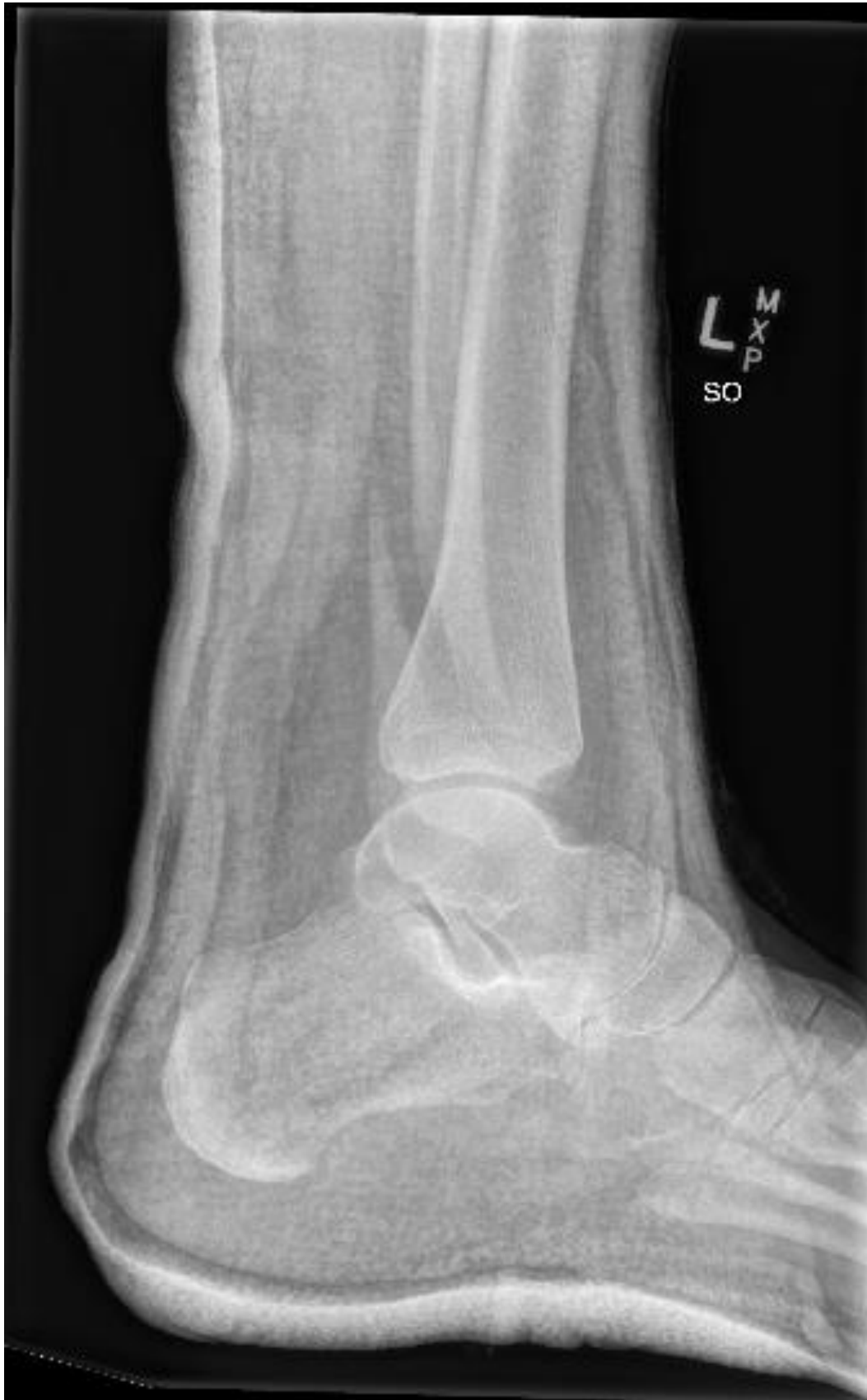2. L Ankle Xray 1: Lateral



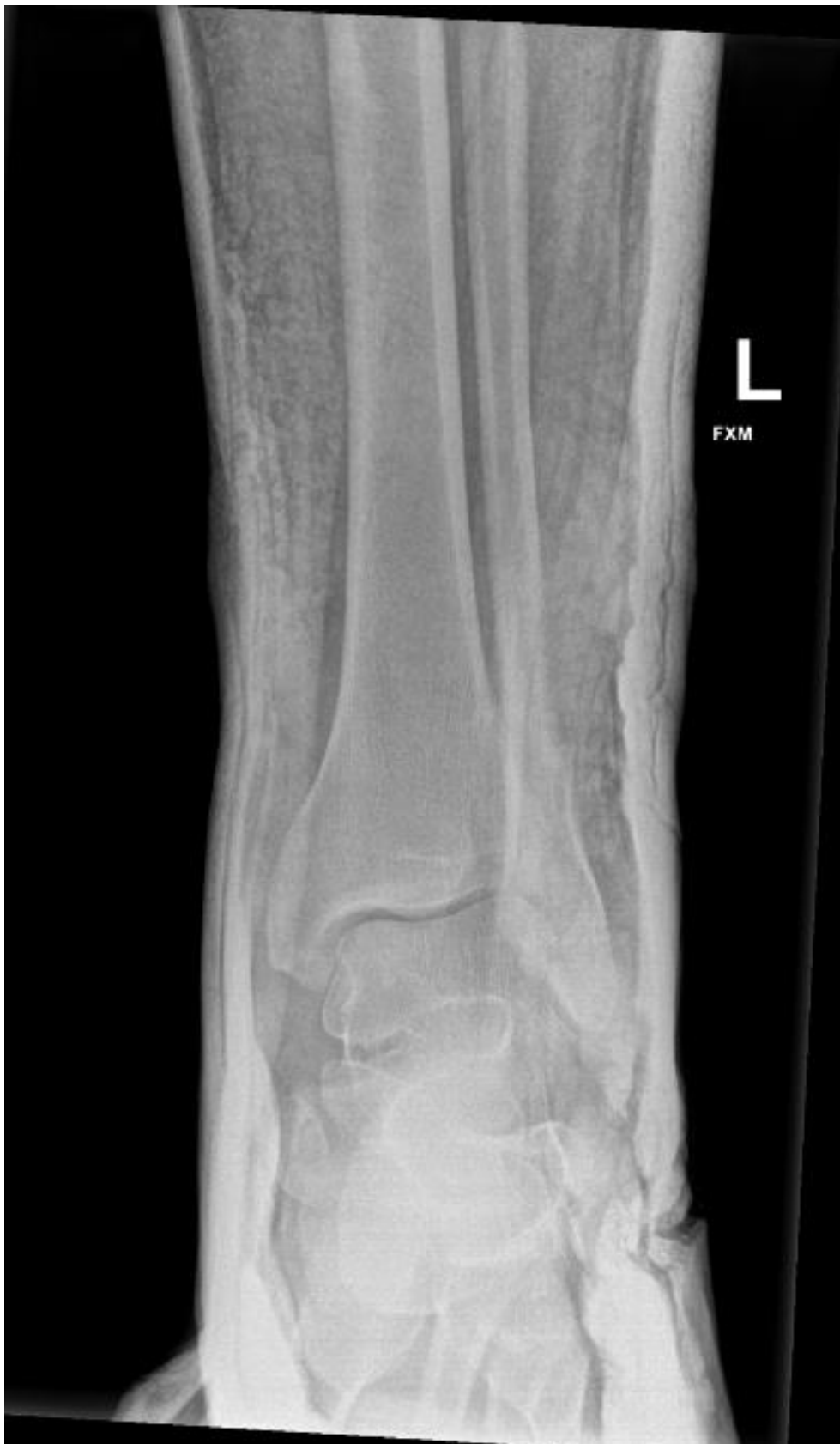3. L Ankle Xray 2: AP



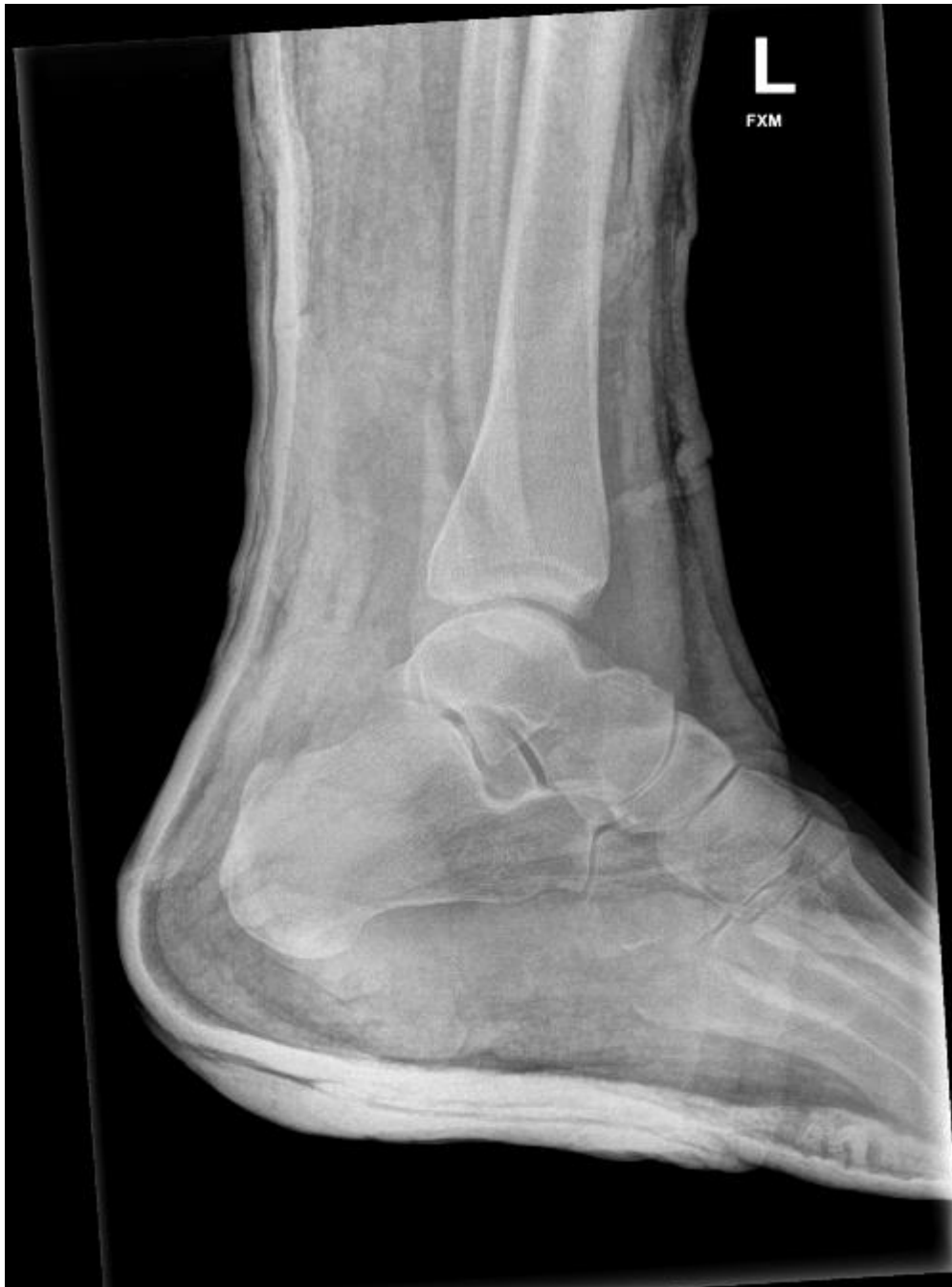4. L Ankle Xray 2: Lateral



5. L Ankle Xray 3: AP



6. L Ankle Xray 3: Lateral



References

1. Ahmetović, D. Prosen, G.(n.d). *Reduction of common fractures and dislocations*. International Emergency Medicine Education Project. <https://iem-student.org/reduction-of-common-fractures-and-dislocations/>
2. Taylor, B.C. (2021, January 12). *Ankle Fractures*. Orthobullets. <https://www.orthobullets.com/trauma/1047/ankle-fractures>

Share your feedback

Please complete our survey to help make Queensland Trauma Education better.

The survey should take no more than 5 minutes to complete.

Scan the QR code or visit:

<https://www.surveymonkey.com/r/3FWL3ZD>



Queensland Trauma Education
Extremity Trauma – Ankle fracture: Case discussion – Training resource kit

Published by the State of Queensland (Clinical Skills Development Service), 2022

Visit csds.qld.edu.au/qte

Email CSDS-Admin@health.qld.gov.au

Phone [+61 7 3646 6500](tel:+61736466500)

